

TISSUE DYSTROPHIES AS A RESULT OF SUBCUTANEOUS INSULIN INJECTIONS CLINICAL AND ULTRASOUND ASPECTS. CASE REPORT

Rodica Perciun

National Institute of Diabetes and Metabolic Diseases “Prof. N. Paulescu”

Abstract

Subcutis tissue pathology induced by the injected drugs, including insulins has not yet a large US evidence. Insulin treatment should be administered into undamaged skin and into subcutaneous fat layers in order to maintain its normal absorption. Systematic rotation of injection sites within the same anatomic area, some individualized injection devices and a specific educational program help to avoid dystrophic lesions. The thickness of the subcutis layer depends on the body mass index, fat distribution and anatomical areas. Needle lengths depend on the subcutis thickness of a given area. Inappropriate needle length repeatedly used or a vicious injection technique are well-known tissue offenders.

A repeated trauma adds mechanical disruption, a sterile or infectious inflammation by itself. Because of this fatty reconstruction, an unpredictable insulin absorption is reached. A carefully and periodically inspection of insulin injection sites should be made, in order to diagnose insulin injected dystrophies. Ultrasonographic appearances must be added to the clinical ones. The insulin treated patients, irrespective of their age, cannot afford to damage many areas during their life-time injection treatment. Due to this fact an US map of the abnormal and available areas should be periodically made.

keywords: insulin injections, tissue dystrophies, ultrasound map

Introduction

Insulin treated diabetic patients are using insulin subcutaneous injections, performed by needles as boluses or by continuous insulin infusion system (insulin pump). In order to preserve their pharmacokinetic, insulins should be injected into specific undamaged subcutis areas. Local tissue dystrophies are the consequence of repeated trauma in the same areas [1, 2, 3]. These well-known side effects are clinically represented by different appearances: lipohypertrophy, lipoatrophy,

nodules with or without inflammatory reactions and dermal dystrophy. The lack of a specific education isn't the single explanation. The insulin absorption from these areas becomes erratic and unpredictable, leading to a glycaemic unbalance [1, 3, 4]. Ultrasonographic (US) interrogation of insulin injected areas is not currently available anywhere.

We have used a diagnostic ultrasound imaging equipment FF sonicUF-750 XT (Fukuda Denshi) and a 7.5-9 MHz linear transducer.

Case report

The paucity of clinical signs is in contrast with the multiple abnormal US appearances in our case report. The same person presents different signs as a result of the local well-known aggressive factors. A 64 year-old man with a 34 years history of insulin injections has announced the escalation of his daily insulin dosage. Previously he had used 70-80u/day but at admission he was using

205u/day in order to maintain the same glycaemic values. This schedule had been self made, bases on his selfmonitoring. The inspection of the areas below the navel, where he had been heavily injected for decades, showed some reddish, warmer hypertrophic areas, spontaneously painless, except when injected. Palpation revealed some deeper nodular entities (Figure 1).

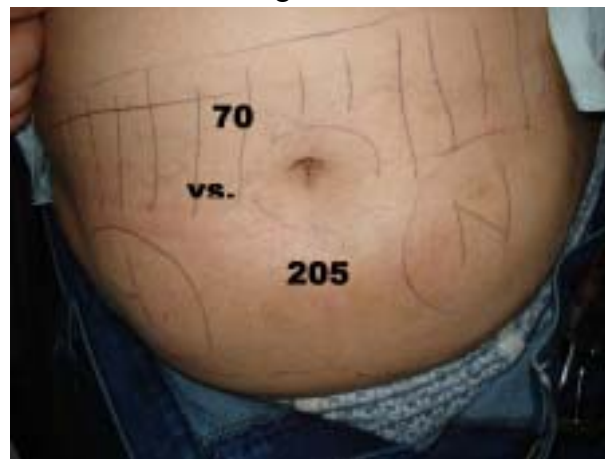

Figure 1. Hypertrophic below navel areas somewhat reddish and warmer by comparison with the above navel areas.

No spontaneous pain only when injected. Palpation reveals some deeper and firmless nodules (marked N in this photo). Erratically insulin absorption from these areas is claiming much more insulin for an almost normal response. Looking for another undamaged area (grid above navel) is mandatory in order to restore insulin demands (205 u vs 70u).

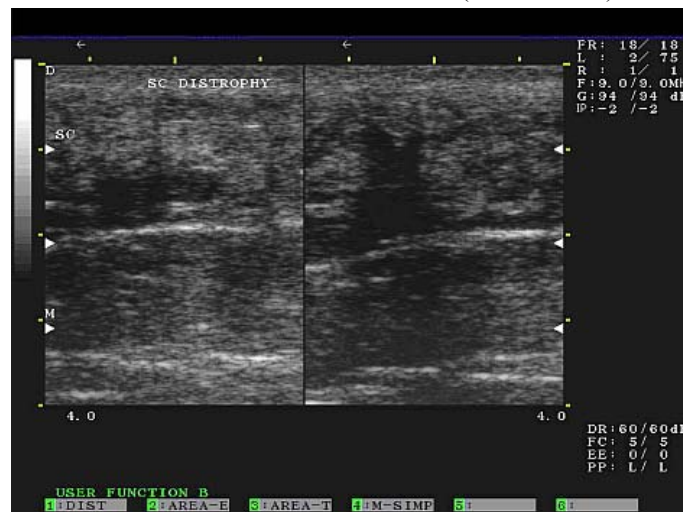


Figure 2. Split screen images showing irregular hypoechoic areas which suggest a necrotic or liquefaction component of a macronodular hyperechoic texture. A previously large haematoma could also be discussed

We decided to inject the normal areas decreasing of the insulin dosage to 70u above the navel, with a rapid and dramatic

roughly/day. A complex US substrate of the affected areas was revealed.

Nodular hypoechoic subcutaneous dystrophy (Figure 2)

- a thickened subcutis layer heterogeneously hyperechoic making indistinct the dermis/subcutis delineation
- both split screen images offer some hypoechoic irregular shaped nuclei as part of macro nodular echotexture; they seem to be necrotic or liquefaction areas (a previously haematoma cannot be excluded)

A hypertrophic inhomogeneous hyperechoic subcutis with hypoechoic halo encircled nodules (Figure 3)

- not clearly delineated dermis/subcutis boundary; some linear hyperechoic entities suggest a fibrotic reaction to the long-lasting trauma. US interrogation also suggests an ongoing macro nodular echotexture supported probably by cellulites.
- many hypoechoic strands, tend to separate fat lobules which remain relatively hyperechoic by comparison, suggesting an inflammatory edema (not necessarily an infectious one).
- deeper we can see some irregular hypoechoic echotexture probably related to a posthaemorrhagic fat necrosis process.

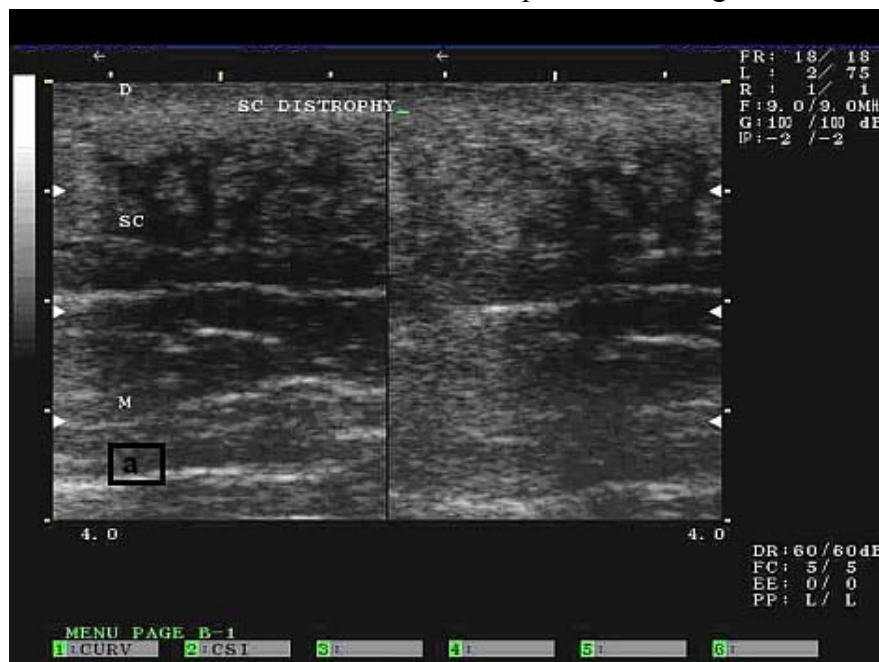


Figure 3. The damaged hyperechogenic subcutis layer with fat lobules encircled by larger hypoechoic strands suggests an advanced nodular shaped edema. The inner and the deeper irregular hypoecogenity does not exclude fat necrosis as a consequence of haemorrhages.

Discussion

Subcutis tissue pathology induced by the injected drugs, including insulins has not yet a large US evidence [5, 6, 7]. Insulin treatment

should be administered into undamaged skin and into subcutaneous fat layers in order to maintain its normal absorption [8]. Systematic rotation of injection sites within the same anatomic area, some individualized injection

devices and a specific educational program help to avoid dystrophic lesions [1]. The thickness of the subcutis layer depends on the body mass index, fat distribution and anatomical areas [1,2,5]. Needle lengths depend on the subcutis thickness of a given area. Inappropriate needle length repeatedly used or a vicious injection technique are well-known tissue offenders [2, 3, 4].

A repeated trauma adds mechanical disruption, a sterile or infectious inflammation by itself [5]. Because of this fatty reconstruction, an unpredictable insulin absorption is reached.

Conclusion

A carefully and periodically inspection of insulin injection sites should be made, in order to diagnose insulin injected dystrophies. Ultrasonographic appearances must be added to the clinical ones. The insulin treated patients, irrespective of their age, cannot afford to damage many areas during their lifetime injection treatment. Due to this fact an US map of the abnormal and available areas should be periodically made.

REFERENCES

1. EADV Guideline "The administration of insulin with the insulin pen" *EADV*, Utrecht. 2008.
2. Polak M, Beregszaszi M, Belarbi N, et al . Subcutaneous or intramuscular injections of insulin in children. Are we injecting where we think we are? *Diabetes Care* 19 (12): 1434-1436, 1996.
3. Chowdhury TA, Escudier V. Poor glycaemic control caused by insulin induced lipohypertrophy. *BMJ* 327: 383-384, 2003.
4. Birkebaek NH, Johansen A, Solvig J. Cutis/subcutis thickness at insulin injection sites and localization of simulated insulin boluses in children with type 1 diabetes mellitus: need for individualization of injection technique? *Diabet Med.* 5: 965-971, 1998.
5. Valle M, Zamorani MP. Skin and Subcutaneous Tissue. In Bianchi S, Martinolli C (eds). *Ultrasound of the musculoskeletal system*, Springer (Berlin, New York) 19-45, 2007.
6. Thow JC, Coulthard A, Home PD. Insulin injection site tissue depth and localization of a simulated insulin bolus using a novel air contrast ultrasonographic technique in insulin treated diabetic subjects. *Diabet-Med.* 9: 915-920, 1992.
7. Hazel E, Poltawski L, Todd A. Sonographic characterization of tissue changes associated with infused apomorphine: a case series. *Ultrasound* 16: 155-159, 2008.
8. Perciun R. *Medical ultrasonography* 12: 104-109, 2010

Correspondence Data:

ZIP :020685

CITY: Bucharest

Phone: 0216192731, mobile:0728542548

e-mail: rodicaperciun@gmail.com

Postal address: Str.Precupetii Vechi nr.20, sector 2

THE TREATMENT OF DIABETIC NEUROPATHY AND THE WAY TO LOWER ITS ECONOMIC BURDEN

Kristina Popova, Atanas Sarandev

Faculty of Public Health, Medical University- Sofia, Bulgaria

Abstract

Many investigations, including ours, offer data about the economic burden of diabetic neuropathy. In Bulgaria the costs of this disease to the society are huge. In 2008, diabetic neuropathy was the eighth cause of hospitalization, imposing relatively high costs on our country. There is a strong connection between diabetic neuropathy and the following factors: patients' age, duration of diabetes mellitus, the presence of micro-vascular changes and finally poor control of the blood glucose level. Data show difficulties in the diagnostics and treatment of neuropathy, this having a negative impact on the prognosis. From an organizational point of view, it is very important to apply screening techniques for the diagnosis of diabetic neuropathy. Considering the present financial situation of the Bulgarian health system, it is critically important that people with diabetes and their medical doctors collaborate in order to create a higher level of practice in the management of the disease. For this process to be effective, the patients have to be accepted as experts and equal members of the therapeutic team. Diabetic neuropathy is a heterogeneous disease with diverse clinical manifestations. It is one of the complications of diabetes that usually occurs in association with chronically elevated blood glucose levels that may damage the nerves, predominantly in the patients' legs.

keywords: *diabetic neuropathy, costs, pharmacoeconomy, alpha-lipoic acid, clinical management.*

Our Bulgarian experience in the clinical management of diabetic neuropathy

A recent study that took place in our country examined 212 patients (122 women and 90 men) hospitalized in eight wards, with different stages of diabetic neuropathy. They were all treated with medical products based on benfotiamin and the effectiveness of the treatment was then evaluated. In the following diagram the effectiveness of the treatment is correlated with the period of time patients were treated. (figure 1).

The mean age of the patients in this study was 44.3 ± 9.8 . The distribution of the patients

according to the duration of diabetes indicates a mean duration of $11.49 \text{ years} \pm 4.6 \text{ years}$. 25% of the patients have a duration of the disease of more than 20 years; 22%: 15-20 years and 20%: 10-15 years. The study proves a statistically significant relationship between the duration of diabetes and the presence of symptoms of diabetic neuropathy - difficulties in the movement, going to bed without need of help, getting dressed and undressed, fornication, feelings of burning and steaming in the feet, pain mainly at night with the same location etc.